

A pilot-study of a minimally invasive technique to elevate the sinus floor membrane and place graft for augmentation using high hydraulic pressure: 18-month follow-up of 20 cases

Philip Jesch, DMD,^a Emanuel Bruckmoser, MD, DMD,^b Andreas Bayerle, MSc, MBA,^c Klaus Eder, MD,^d Michaela Bayerle-Eder, MD, PhD,^e and Franz Watzinger, MD, DMD, PhD^f

Dental Clinic Wienerberg City, Vienna, Austria; Morrision Hospital, Wales, UK; Jeder GmbH, Dental Technology, Vienna, Austria; Private Practice for General Dentistry and Implantology, Vienna, Austria; Medical University of Vienna, Vienna, Austria; and St. Poelten General Hospital, Austria

Objective. To evaluate medical efficacy and safety of crestal, minimally invasive sinus floor augmentation (MISFA) using an innovative method based on high hydraulic pressure.

Study design. Twenty MISFA using the novel Jeder-System were performed in 18 patients at 2 study sites in Vienna, Austria. The Jeder-System consists of the Jeder-drill, the Jeder-pump, and a connecting tube-set. The pump generates high hydraulic pressure (1.5 bar) pushing back the sinus membrane from the drill at the first perforation. The pump also monitors the whole procedure by constantly measuring pressure and volume.

Results. Five percent membrane perforation rate (1/20) only detected in the postoperative computed tomography scan and without implication for implant placement. Height gain of 9.2 ± 1.7 mm achieved (from 4.6 ± 1.4 mm to 13.8 ± 2.3 mm). Average patient satisfaction was 9.82 on scale from 1 to 10 (10 = very satisfied). Mean duration of sick leave was 0.19 days. 18-month survival rate was 95% (1/20 implant lost).

Conclusions. Within the limits of a prospective open cohort study with 20 cases, our data demonstrate the safety and medical efficacy of the novel method. (Oral Surg Oral Med Oral Pathol Oral Radiol 2013;116:293-300)

Although the lateral window technique using a modified Caldwell-Luc approach still represents the standard procedure for sinus floor augmentation in the posterior maxilla region, patients frequently suffer from considerable postoperative pain and swelling.

Therefore, substantial efforts have been made to develop less invasive techniques in order to reduce patient discomfort. As a first improvement of that kind a transalveolar technique with subsequent implantation was introduced by Tatum¹ and further developed as an osteotome technique by Summers.² The controlled primary entry of the drill into the maxillary sinus and the safe elevation of the Schneiderian membrane without perforation are the major challenges of this method. The shortcomings of the Summers technique have motivated

A potential conflict of interest is declared by P. Jesch, A. Bayerle, K. Eder, and M. Bayerle-Eder since these authors have commercial associations with the Jeder GmbH, Dental Technology, Vienna, Austria.

^aOral Surgeon, Dental Clinic Wienerberg City.

^bRegistrar, Department of Oral and Maxillofacial Surgery, Morrision Hospital.

^cCEO, Jeder GmbH, Dental Technology.

^dOral Surgeon, Private Practice for General Dentistry and Implantology.

^eAssociate Professor, Department of Internal Medicine III, Medical University of Vienna.

^fProfessor and Head, Department of Oral and Maxillofacial Surgery, St. Poelten General Hospital.

Received for publication Mar 26, 2013; returned for revision May 6, 2013; accepted for publication May 15, 2013.

© 2013 Elsevier Inc. All rights reserved.

2212-4403/\$ - see front matter

<http://dx.doi.org/10.1016/j.oooo.2013.05.014>

the development of a great variety of new methods over the past 15 years. Recent publications on these modifications cover the use of balloons³⁻⁵ and hydraulic pressure in humans,⁶ the appliance of a hydraulic sinus condensing technique,⁷ a gel-pressure technique,^{8,9} as well as the use of “intelligent” drills.^{10,11}

In a systematic review of 10 transcrestal sinus lift studies, Tan¹² identified a reported membrane perforation rate of 0%-21.4% (mean 3.8%). However, in a parallel review of 33 clinical studies using the lateral approach, Pjetursson¹³ reported a perforation rate of 0%-58.3% (mean 19.5%). Based on this, Watzek¹⁴ rightly doubts the validity of the numbers reported by Tan. As the lateral window technique is done with visual control, it seems unlikely that the perforation rate should be much lower for “blind” procedures in which there is no more than the surgeon’s tactile perception to go by. Rather, we agree with Watzek¹⁴ and Rosen¹⁵ that using the transcrestal approach clinically insignificant perforations are generally not detected. Therefore,

Statement of Clinical Relevance

Currently there are only a few techniques for flapless minimally invasive sinus floor augmentation available. We present a novel procedure, which tackles shortcomings of other techniques, like secure entry into the maxillary sinus and controlled elevation of the Schneiderian membrane.

one can assume that the actual transcresal perforation rates are much higher than those reported by Tan.

In his review, Tan also identified a reported mean implant success rate of 92.8% for transcresal sinus elevations. However, Tan confirmed the finding of Rosen¹⁶ that the implant failure rate increased with and was correlated to reduced residual bone height.

It was therefore the aim of the present study to evaluate the safety and medical efficacy – in particular in terms of membrane perforation rate and 18-month survival rate – of the novel technique for minimally invasive sinus floor augmentation (MISFA) using the Jeder-System (Jeder GmbH, Vienna, Austria).

MATERIALS AND METHODS

Patient selection

Recruitment and selection of patients took place at the 2 study sites in Vienna, Austria, where the surgical procedures were to be performed. All subjects gave written informed consent to the protocol, which was in compliance with the Helsinki Declaration and had been approved by the Ethics Committee of the City of Vienna, Austria. Study monitor was the Coordination Center for Clinical Studies of the Medical University of Vienna.

Inclusion criteria were as follows: women and men aged 18 years or older, 1 or more missing upper first or second premolars or upper first or second molars, and bone atrophy in the posterior maxilla region resulting in a residual alveolar ridge height of <8 mm.

Exclusion criteria were as follows: residual alveolar ridge height of <3 mm impeding implantation directly after augmentation, Underwood septa localized in intended implant position, sinus membrane thickness >5 mm, maxillary sinusitis or polyposis, pregnant or breastfeeding women, poor oral hygiene, tobacco consumption of more than 15 cigarettes per day, hypercortisolism, corticoid treatment, osteoporosis with intravenous bisphosphonate therapy, subjects suffering from severe chronic diseases as well as immune-suppressed patients.

Pre-operative evaluation

A questionnaire, a clinical examination, a panoramic radiograph and a dental computed tomography (CT) scan were performed to assess inclusion and exclusion criteria. Women of reproductive age had to submit a negative pregnancy test before every CT scan. In case of a positive test result the CT scan would not be performed and the subject would not be included in the study.

Study population

From September 2010 through February 2011, a total number of 18 consecutive patients were recruited and

Table I. Subjects characteristics

Male/female				7/11
Age range (years)				29-77
Chronic disease/medication				5
Smoker				0

Data are presented as absolute numbers ($n = 18$).

Table II. Number and position of sinus lifts according to the World Health Organization (WHO)/Fédération Dentaire Internationale (FDI) system

No. of sinus lifts	6	5	3	6
Position (WHO/FDI)	16	15	25	26

Data are presented as absolute numbers ($n = 20$).

selected for 20 MISFA with subsequent immediate implant placement. The patient population consisted of 11 women and 7 men aged 29-77 years (51 ± 16 years). In 2 subjects MISFA was performed bilaterally. A total of 5 patients suffered from 1 or 2 of the following diseases requiring permanent medication: hypertension ($n = 4$), cardiac arrhythmia ($n = 1$), hyperlipidemia ($n = 1$), restless legs syndrome ($n = 1$). All patients were non-smokers. Patients' characteristics are summarized in Table I.

Sixty percent of the implants were placed in the position of the upper first molar and 40% were placed in the position of the upper second premolar (see Table II).

The residual bone height was 4.6 ± 1.4 mm. The thickness of the Schneiderian membrane was 1.6 ± 0.5 mm. The bone quality¹⁷ was as follows: type 2 in 1 case, between type 2 and 3 in 3 cases, and type 3 in the remaining 16 cases (see Table III).

Surgical procedure

All sinus lift procedures were performed by using the Jeder-System (Figure 1) which is fully CE-certified and distributed by Jeder GmbH, Vienna, Austria (www.jedersystem.com). The system consists of the Jeder-drill (Jeder GmbH, Vienna, Austria) (the actual surgical tool) (Figure 2), the Jeder-pump (Jeder GmbH, Vienna, Austria) (Figure 3), and a connecting tube-set. The pump generates high hydraulic pressure (1.5 bar) in the pressure-sealed system, thus pushing back the sinus membrane from the drill at the slightest perforation of the remaining bone. The pump also generates hydraulic vibrations to further raise and separate the membrane from the bone. The whole procedure is controlled by constantly measuring pressure and volume of the inserted fluid.

A surgical procedure using the Jeder-System consists of the following steps:

- Initially, a soft tissue punch (ATP-punch, DENTSPLY-Friadent, Mannheim, Germany) (Figure 4) is used at the implantation site without mucoperiosteal flap

Table III. Summary of pre- and postoperative clinical and radiologic data of the study

Sinus lifts	Pre-operative residual bone height (mm)	Pre-operative sinus membrane thickness (mm)	Bone quality (Lekholm/Zarb index ¹⁷)	Height gain (mm)	Total postoperative bone height (mm)	Implant length (mm)	Volume augmentation material (mL)
1	7	1.5	3	6	13	11	0.70
2*	4	2	3	7	11	11	0.70
3*	4	1	3	11	15	11	0.70
4	4	2	3	10	14	11	0.85
5	3	1.5	3	11	14	11	0.75
6	3	1.5	3	6.5	9.5	9.5	0.60
7	4	2	3	7	11	11	0.95
8	3	3	3	8	11	11	0.80
9	4	2	2	9	13	11	0.85
10	4	2	3	11	15	11	0.95
11	4	1.5	3	9	13	11	0.85
12	5	2	3	10	15	11	0.95
13	7	1	2.5	10	17	11	1.00
14	4	1	3	11	15	11	0.85
15*	7	1.5	2.5	11	18	11	0.70
16*	4	1.5	2.5	8	12	11	0.70
17	4	1	3	9	13	11	1.05
18	4	1	3	9	13	11	0.85
19	7	2	3	10	17	14	0.75
20	6	1	3	11	17	11	0.75
Mean ± SD	4.6 ± 1.4	1.6 ± 0.5	2.9 ± 0.3	9.2 ± 1.7	13.8 ± 2.3	11.0 ± 0.7	0.8 ± 0.12

SD, standard deviation.

*Sinus lift performed bilaterally in 1 session.



Fig. 1. Jeder-System: pump with foot pedal, drill, and connecting tubing set.

retraction. Then, the primary drill is taken until 1-2 mm below the sinus floor. To verify depth, an intra-operative radiograph can be done (Figure 5).

- Once the primary drilling has reached a sufficient depth shortly below the sinus floor, the Jeder-drill is plugged into the bore (pressure-sealed) (Figure 6) and high hydraulic pressure (1.5 bar) is built up in the pressure chamber of the Jeder-drill using physiological saline solution (NaCl). The centrally placed drill within the pressure chamber of the Jeder-drill slowly moves through the remaining crestal bone toward the sinus floor (Figure 7).
- Upon the first minimal perforation of the remaining bone, the pressurized fluid pushes back the membrane, ensuring that the drill does not perforate

the membrane (Figure 8). At the same time, a sudden drop in pressure on the display of the Jeder-pump indicates the successful first entry into the sinus to the surgeon (Figure 9).

- After the perforation of the remaining bone, the saline solution – which is set into hydraulic vibrations (50 Hz) by the Jeder-pump – further separates the membrane from the bone. Thereby, space for the augmentation material and the implant is created. After extraction of the saline solution using the Jeder-pump the augmentation material and the implant are inserted (Figure 10).
- The whole procedure is constantly monitored by continuous measurement of the pressure and volume of the inserted fluid on the display of the Jeder-pump. The Jeder-pump features a built-in security mechanism to prevent introducing excessive pressure and fluid volume: As each step on the foot pedal of the Jeder-pump injects only 0.2 mL of saline solution, there is no danger for the Schneiderian membrane after the perforation of the bone (“high pressure, but very limited amount of liquid”). Additionally, all data are electronically recorded for documentation purposes.

A combination of Ostim (Heraeus Kulzer, Vienna, Austria) and Bio-Oss (Geistlich Biomaterials, Baden-Baden, Germany) was used as augmentation material. In total, 20 Ankylos screw type implants (DENTSPLY-Friadent, Mannheim, Germany) were placed immediately after MISFA. Implant diameters were 3.5 mm in




Fig. 2. The Jeder-drill consists of the guide-element and the centrally placed drill.

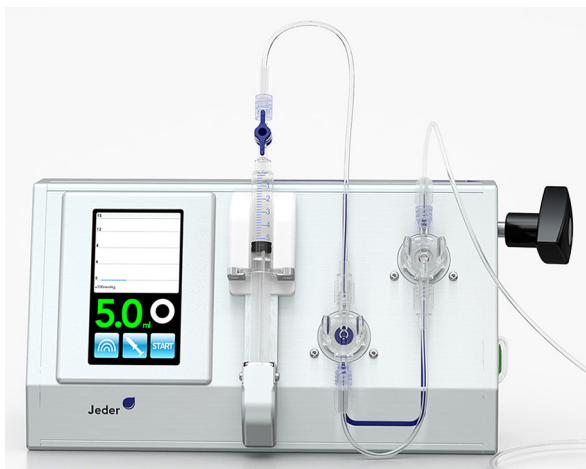


Fig. 3. The Jeder-pump with control display, controlled by foot pedal.

4 cases and 4.5 mm in 16 cases. Implant length was 11 mm in all but 2 cases. One implant was 9.5 mm long while another one was 14 mm.

Peri- and postoperative care

Prior to surgery local anesthetic infiltration was administered buccally and palatally (articaine hydrochloride 4% with epinephrine 1:100,000 [Septanest with Epinephrine; Septodont, Niederkassel-Mondorf, Germany]). Postoperatively, patients were prescribed either clindamycin hydrochloride 300 mg (Clindac; Sandoz GmbH, Kundl, Austria) 3 times daily or josamycin 500 mg (Josalid; Sandoz) twice a day, for 1-week period. Following successful implantation the healing period until full

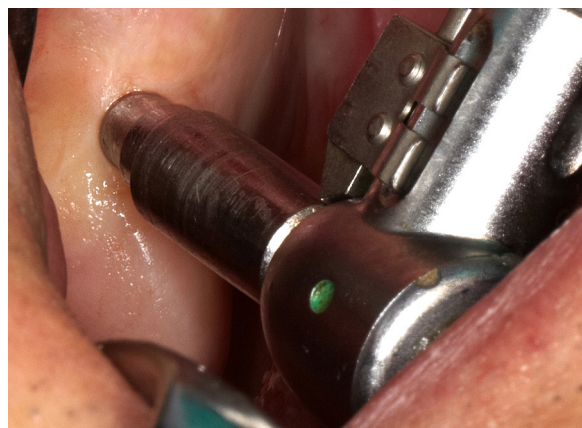


Fig. 4. The ATP-punch, developed by Prof. Dr. Wolfgang Jesch.

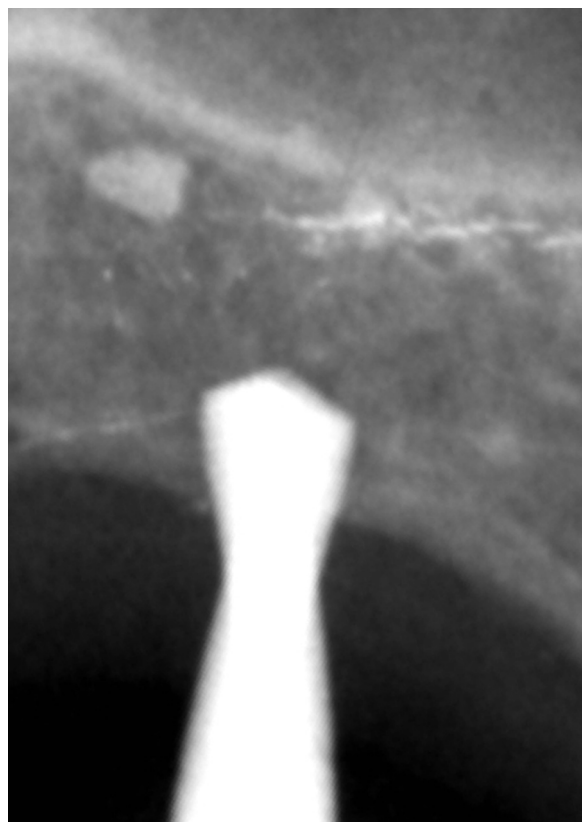


Fig. 5. The depth of the primary drill can be verified by taking an intra-operative radiograph.

implant load was 258 ± 81 days. Prosthetic rehabilitation included single crowns in 12 cases, implant bridge constructions in 6 cases (including 1 horseshoe implant bridge), and removable partial dentures in 2 patients.

Clinical and radiologic follow-up

On day 1 and day 3 after surgery, telephone follow-ups were conducted. One week postoperatively, every

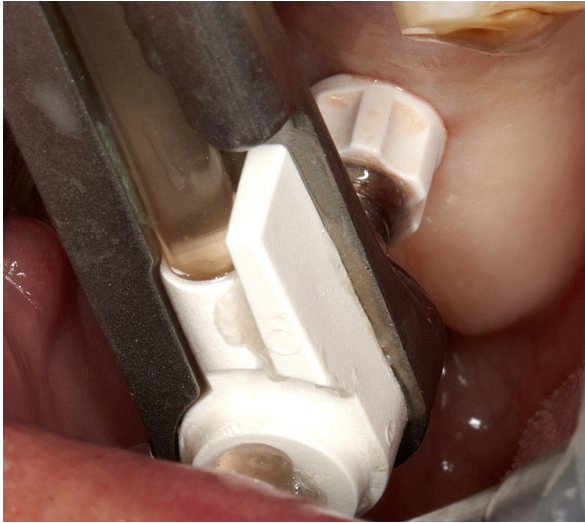

Fig. 6. The sealing element of the Jeder-drill (Jeder GmbH, Vienna, Austria) is pressed against the mucosa.




Fig. 7. Hydraulic pressure is built up in the pressure chamber of the Jeder-drill (Jeder GmbH, Vienna, Austria) using physiological saline solution.

patient completed a questionnaire including the degree of overall patient satisfaction – by use of a visual analog scale (VAS) (1 = not satisfied, 10 = very satisfied) – and including the days of sick leave. Between 4 and 6 weeks after surgery, a clinical examination and a control CT scan were performed aiming at detecting possible post-operative complications (e.g., sinusitis or sinus membrane perforation) as well as quantification of height gained by the augmentation procedure. All CT images were evaluated by 2 independent investigators not involved in the surgical procedures.

Eighteen months postoperatively (562 ± 34 days) implant stability was assessed in a clinical and radiologic [periapical radiograph and digital volume tomography (DVT)] examination. The survival criteria proposed by Buser et al.¹⁸ and Cochran et al.¹⁹ were followed at the 18-month control. They included the following: (1)

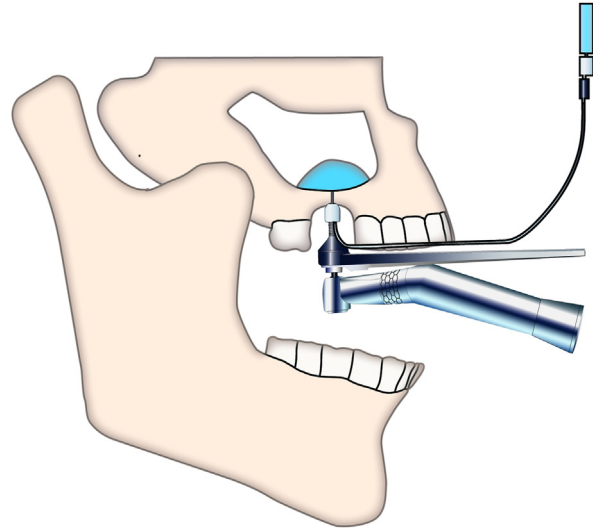


Fig. 8. The high pressure pushes the Schneiderian membrane away from the drill.

absence of clinically detectable implant mobility, (2) absence of pain or any subjective sensation, (3) absence of recurrent peri-implant infection, and (4) absence of continuous radiolucency around the implant.

Statistical analysis

Descriptive statistical analysis including calculation of mean values and standard deviation (SD) of recorded data was carried out with Statistica software (release 6.0, StatSoft Inc., Tulsa, OK, USA). Data are presented as means \pm SD.

RESULTS

In total, 20 MISFA were performed in 18 patients. Main data are summarized in Table III.

On the control CT scan performed 4-6 weeks post-operatively, a small amount of augmentation material was observed in a maxillary recessus in 1 out of 20 cases. Thus, the membrane perforation rate was 5%. The patient did not show any clinical symptoms and there was no implication for the implant placement. The respective patient is under close observation and at the 18-month follow-up there were no clinical symptoms related to this perforation of the Schneiderian membrane.

The control CT scan also showed that the residual bone height of 4.6 ± 1.4 mm could be augmented to 13.8 ± 2.3 mm corresponding to a height gain of 9.2 ± 1.7 mm.

Overall patient satisfaction with the surgical procedure was evaluated based on a questionnaire using a VAS ranging from 1 to 10 (1 = not satisfied, 10 = very satisfied). Average patient satisfaction was 9.82 ± 0.7 points. The mean duration of sick leave was 0.19 ± 0.5 days.

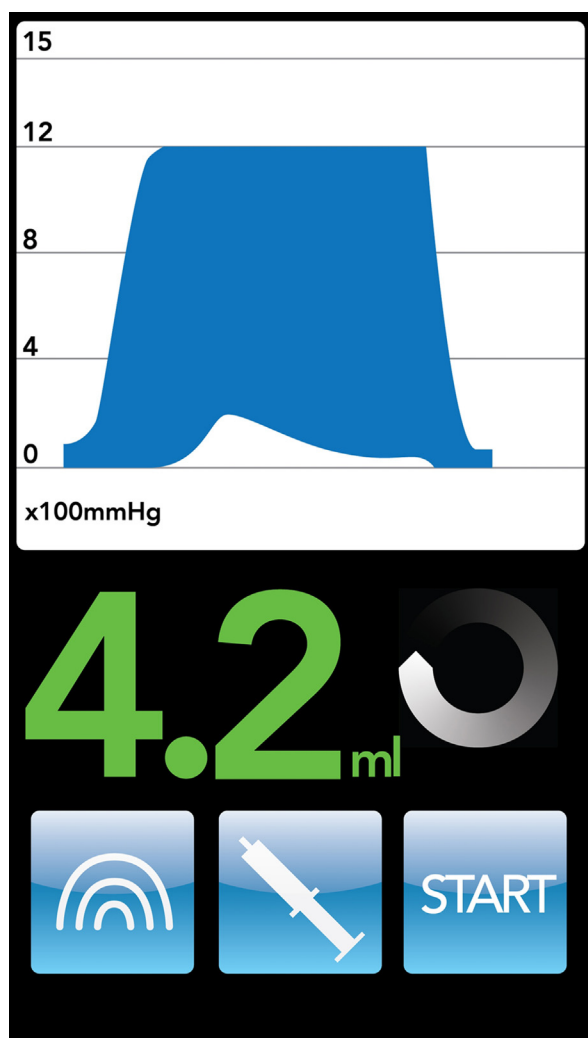


Fig. 9. The pressure-drop on the display of the Jeder-pump (Jeder GmbH, Vienna, Austria) indicates the successful perforation of the remaining bone.

At the 18-month follow-up, none of the implants showed any mobility apart from 1 case where the implant was lost 9 months after surgery. Following insertion of a new implant at the same site 3 months after explantation, the new implant is still in place and functions well according to the patient's feedback. The 18-month survival rate was therefore 95% (19 of 20 implants). None of the remaining implants showed any mobility, and there was no pain, redness, swelling, or suppuration at any implant site. None of the patients reported clinical symptoms of maxillary sinusitis, and also the DVT did not reveal any case of sinusitis.

DISCUSSION

The main finding of our study is that — within the limits of a prospective open cohort study with 20 cases — MISFA using the Jeder-System is a safe and effective

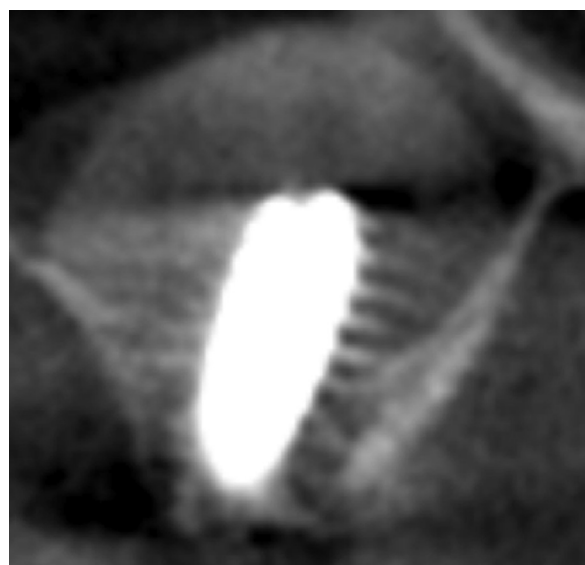


Fig. 10. The postoperative DVT shows the sinus lift and the implant in situ.

method for cases with at least 3 mm residual alveolar ridge height.

Height gain

It is widely accepted in the literature that crestal methods currently in use are not predictable and reproducible if elevations >5 mm are needed.^{20,21} However, in the present study the height gain ranged from 6 to 11 mm (mean 9.2 ± 1.7 mm). In cadaveric studies it has been demonstrated that in a crestal approach the Schneiderian membrane can be lifted more than 10 mm without tearing.^{8,22} Membrane perforation can occur as soon as elevation forces exceed the load limits of the sinus membrane.⁸ As the Jeder-System uses hydraulic pressure, Pascal's principle of even pressure distribution applies¹¹ and allows optimized force transmission. Therefore, it can be concluded that the novel method can deliver a height gain that is comparable to the lateral approach.

Perforation rate

In the literature, perforation rates for indirect sinus floor augmentations usually vary between 0% and 44%.^{9,12,15,23} In reality, microscopic tears are, in many instances, impossible to diagnose and therefore their incidence frequency is often underestimated.^{14,15} Some authors²⁴⁻²⁶ explicitly state that small perforations (without clinical verification) might not have been detected, which means that the perforation rates reported in their studies would be too low.

In an endoscopically controlled osteotome sinus floor augmentation study, the validity of the Valsalva maneuver was questioned due to the limited

effectiveness to detect small perforations of the Schneiderian membrane.²⁷ In our study, CT scans were undertaken before and 4-6 weeks after MISFA in all patients. Additionally, all CT images were evaluated by 2 independent investigators not involved in the surgical procedure. In one patient a small amount of augmentation material was radiologically visible in the upper recessus of the maxillary sinus without any clinical symptoms of sinusitis. Therefore, membrane perforation rate was considered to be 5% (1 of 20 cases). The perforation neither affected implant stability nor caused any problems for the patient. At the 18-month follow-up visit, the patient demonstrated no clinical symptoms or radiological signs of sinusitis and the implant loading was successful. We can confirm the finding^{9,22,28} that small membrane perforations are compatible with clinically healthy postoperative sinus conditions.

Survival rate

In his systematic review of 10 transcresal sinus lift studies, Tan¹² identified a reported mean implant success rate of 92.8%. This is almost the same as for implants placed in the posterior maxilla without grafting, i.e., 95.9%-97.7%.^{14,29} Watzek¹⁴ rightly remarks that the residual local bone height of 6-7 mm usually recommended for transcresal sinus floor elevation means that implants of appropriate length should be firmly seated in the host bone. Therefore, at least in the first few years, Watzek considers it difficult to say whether implant stability was achieved because of transcresal sinus floor elevation or on account of the bone volume-related short osseointegration segment sufficient for short implants.

For a residual bone height below the recommended range, the story is different. Without quantifying the effect, Tan¹² confirms the finding of Rosen¹⁶ that the failure rate of the implants increased with and was correlated to reduced residual bone height. In a multicenter retrospective study, Rosen reported a survival rate of 96%, when the residual bone height was 5 mm or more, but the survival rate decreased to 85.7%, when the residual bone height was 4 mm or less. Watzek¹⁴ rightly remarks that at a residual bone height of <4 mm, implant survival has rarely been reported. In his own recent study with the gel-pressure technique, Watzek⁹ reports an implant survival rate 1 year after implant placement of 88.5% at sites with a pre-operative bone height of at least 4 mm ($n = 26$). This decreases to a 1 year survival rate of 50.0% for sites with a pre-operative bone height of <4 mm ($n = 14$).

In our study, the survival rate 18 months after implant placement was 94.1% at sites with a pre-operative bone height of at least 4 mm ($n = 17$) and 100% for sites with a pre-operative bone height of <4 mm ($n = 3$). Due to the small number of cases with residual bone height of

<4 mm, further studies are needed to verify that the novel method can also yield high survival rates for sites with pre-operative bone height of <4 mm.

Side effects

All recorded side effects were considered slight or moderate. In particular, there were no signs of infection, sinusitis or nose bleeding after MISFA, while one hematoma was observed after local anesthesia. It could be shown that the novel method significantly reduces side effects compared to the considerably more invasive lateral approach. Thus, sick leave was very low in the present study at 0.17 ± 0.5 days compared to 4.5 ± 3.2 days after the lateral procedure (unpublished own data). Overall patient satisfaction was 9.87 ± 0.7 points on a VAS from 1 = not satisfied to 10 = very satisfied.

CONCLUSIONS

Within the limits of a prospective open cohort study with 20 cases, our data demonstrate the safety and medical efficacy of MISFA using the novel method. A height gain of 9.2 ± 1.7 mm could be achieved. In only one case a membrane perforation occurred without any clinical consequences. The 18-month survival rate was 95%. Side effects were acceptable and remarkably lower compared with the lateral approach. Sick leave occurrence was very low and overall patient satisfaction very high. To further evaluate the Jeder-System a broader clinical study (~ 100 cases) with international study centers is planned in the near future.

REFERENCES

1. Tatum H Jr. Maxillary and sinus implant reconstructions. *Dent Clin North Am.* 1986;30:207-229.
2. Summers RB. A new concept in maxillary implant surgery: the osteotome technique. *Compendium.* 1994;15:152, 154-156.
3. Hu X, Lin Y, Metzmacher AR, Zhang Y. Sinus membrane lift using a water balloon followed by bone grafting and implant placement: a 28-case report. *Int J Prosthodont.* 2009;22:243-247.
4. Kfir E, Goldstein M, Yerushalmi I, et al. Minimally invasive antral membrane balloon elevation – results of a multicenter registry. *Clin Implant Dent Relat Res.* 2009;11(suppl 1):e83-e91.
5. Rodrigues GN, Katayama AY, Cardoso RF. *Subantral Augmentation Utilizing the Zimmer Sinus Lift Balloon Technique.* 2010. Available at: http://www.zimmerdental.com/pdf/lib_artSubAugUtilSLB.pdf. Accessed March 3, 2013.
6. Sotirakis EG, Gonshor A. Elevation of the maxillary sinus floor with hydraulic pressure. *J Oral Implantol.* 2005;31:197-204.
7. Chen L, Cha J. An 8-year retrospective study: 1100 patients receiving 1557 implants using the minimally invasive hydraulic sinus condensing technique. *J Periodontol.* 2005;76:482-491.
8. Pommer B, Watzek G. Gel-pressure technique for flapless transcresal maxillary sinus floor elevation: a preliminary cadaveric study of a new surgical technique. *Int J Oral Maxillofac Implants.* 2009;24:817-822.
9. Watzek G, Pommer B. Clinical experiences using innovative equipment. In: Watzek G, ed. *The Percresal Sinus Lift – From Illusion to Reality.* London: Quintessence Publishing; 2012.

10. Kim JY. Minimally invasive sinus elevation (MISE): is it really possible? *Dent Implantol Update*. 2008;19:65-71.
11. Kim DY, Itoh Y, Kang TH. Evaluation of the effectiveness of a water lift system in the sinus membrane-lifting operation as a sinus surgical instrument. *Clin Implant Dent Relat Res*. 2012;14:585-594.
12. Tan WC, Lang NP, Zwahlen M, Pjetursson BE. A systematic review of the success of sinus floor elevation and survival of implants inserted in combination with sinus floor elevation. Part II: trans-alveolar technique. *J Clin Periodontol*. 2008;35(8 suppl):241-254.
13. Pjetursson BE, Tan WC, Zwahlen M, Lang NP. A systematic review of the success of sinus floor elevation and survival of implants inserted in combination with sinus floor elevation. *J Clin Periodontol*. 2008;35(8 suppl):216-240.
14. Watzek G, Fügl A. Compromised results and complications. In: Watzek G, ed. *The Percrestal Sinus Lift – From Illusion to Reality*. London: Quintessence Publishing; 2012.
15. Rosen PS. Complications with the bone-added osteotome sinus floor elevation: etiology, prevention, and treatment. In: Froum SJ, ed. *Dental Implant Complications: Etiology, Prevention, and Treatment*. Chichester, UK: John Wiley & Sons; 2010.
16. Rosen PS, Summers R, Mellado JR, et al. The bone-added osteotome sinus floor elevation technique: multicenter retrospective report of consecutively treated patients. *Int J Oral Maxillofac Implants*. 1999;14:853-858.
17. Lekholm U, Zarb G, Branemark P. *Tissue Integrated Prostheses: Osseointegration in Clinical Dentistry*. Chicago: Quintessence; 1985:199-209.
18. Buser D, Mericske-Stern R, Bernard JP, et al. Long-term evaluation of non-submerged ITI implants. Part 1: 8-year life table analysis of a prospective multi-center study with 2359 implants. *Clin Oral Implants Res*. 1997;8:161-172.
19. Cochran DL, Buser D, ten Bruggenkate CM, et al. The use of reduced healing times on ITI implants with a sandblasted and acid-etched (SLA) surface: early results from clinical trials on ITI SLA implants. *Clin Oral Implants Res*. 2002;13:144-153.
20. Bassi MA, Lopez MA. Hydraulic sinus lift: a new method proposal. *J Osteol Biomat*. 2010;1:93-101.
21. Reiser GM, Rabinovitz Z, Bruno J, Damoulis PD, Griffin TJ. Evaluation of maxillary sinus membrane response following elevation with the crestal osteotome technique in human cadavers. *Int J Oral Maxillofac Implants*. 2001;16:833-840.
22. Baumann A, Ewers R. [Minimally invasive sinus lift. Limits and possibilities in the atrophic maxilla]. *Mund Kiefer Gesichtschir*. 1999;3(suppl 1):S70-S73.
23. Artzi Z, Parson A, Nemcovsky CE. Wide-diameter implant placement and internal sinus membrane elevation in the immediate postextraction phase: clinical and radiographic observations in 12 consecutive molar sites. *Int J Oral Maxillofac Implants*. 2003;18:242-249.
24. Krennmair G, Krainhofner M, Schmid-Schwab M, Piehlinger E. Maxillary sinus lift for single implant-supported restorations: a clinical study. *Int J Oral Maxillofac Implants*. 2007;22:351-358.
25. Nedir R, Bischof M, Vazquez L, Szmukler-Moncler S, Bernard JP. Osteotome sinus floor elevation without grafting material: a 1-year prospective pilot study with ITI implants. *Clin Oral Implants Res*. 2006;17:679-686.
26. Toffler M. Osteotome-mediated sinus floor elevation: a clinical report. *Int J Oral Maxillofac Implants*. 2004;19:266-273.
27. Nkenke E, Schlegel A, Schultze-Mosgau S, Neukam FW, Wiltfang J. The endoscopically controlled osteotome sinus floor elevation: a preliminary prospective study. *Int J Oral Maxillofac Implants*. 2002;17:557-566.
28. Berengo M, Sivoletta S, Majzoub Z, Cordioli G. Endoscopic evaluation of the bone-added osteotome sinus floor elevation procedure. *Int J Oral Maxillofac Surg*. 2004;33:189-194.
29. Pommer B, Frantal S, Willer J, Posch M, Watzek G, Tepper G. Impact of dental implant length on early failure rates: a meta-analysis of observational studies. *J Clin Periodontol*. 2011;38:856-863.

Reprint requests:

Emanuel Bruckmoser, MD, DMD
Department of Oral and Maxillofacial Surgery
ABM University Health Board
Morrison Hospital
Swansea SA6 6NL, Wales, UK
emanuel.bruckmoser@wales.nhs.uk